

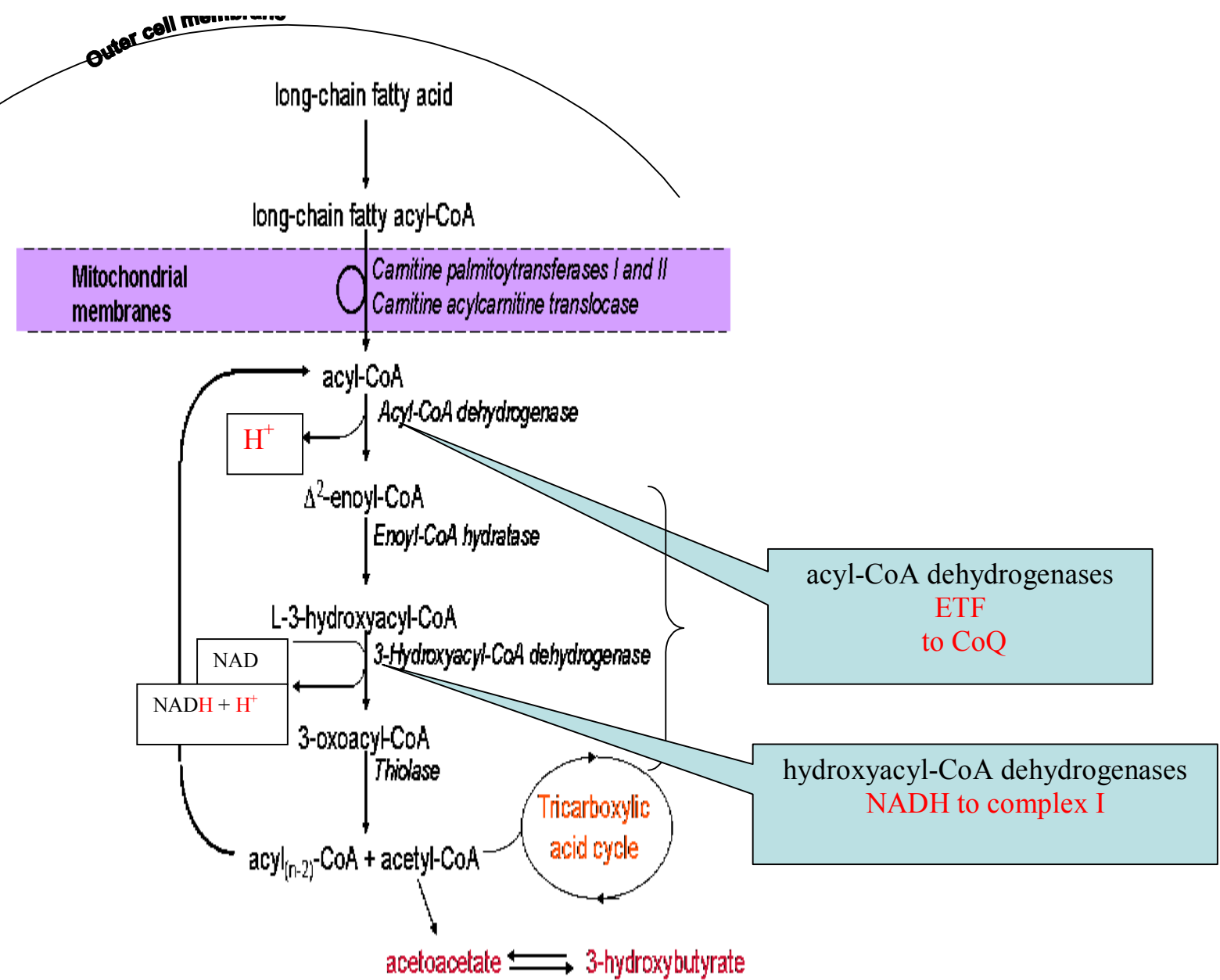
Fat oxidation and defects of the mitochondrial respiratory chain

Dr. Simon Olpin

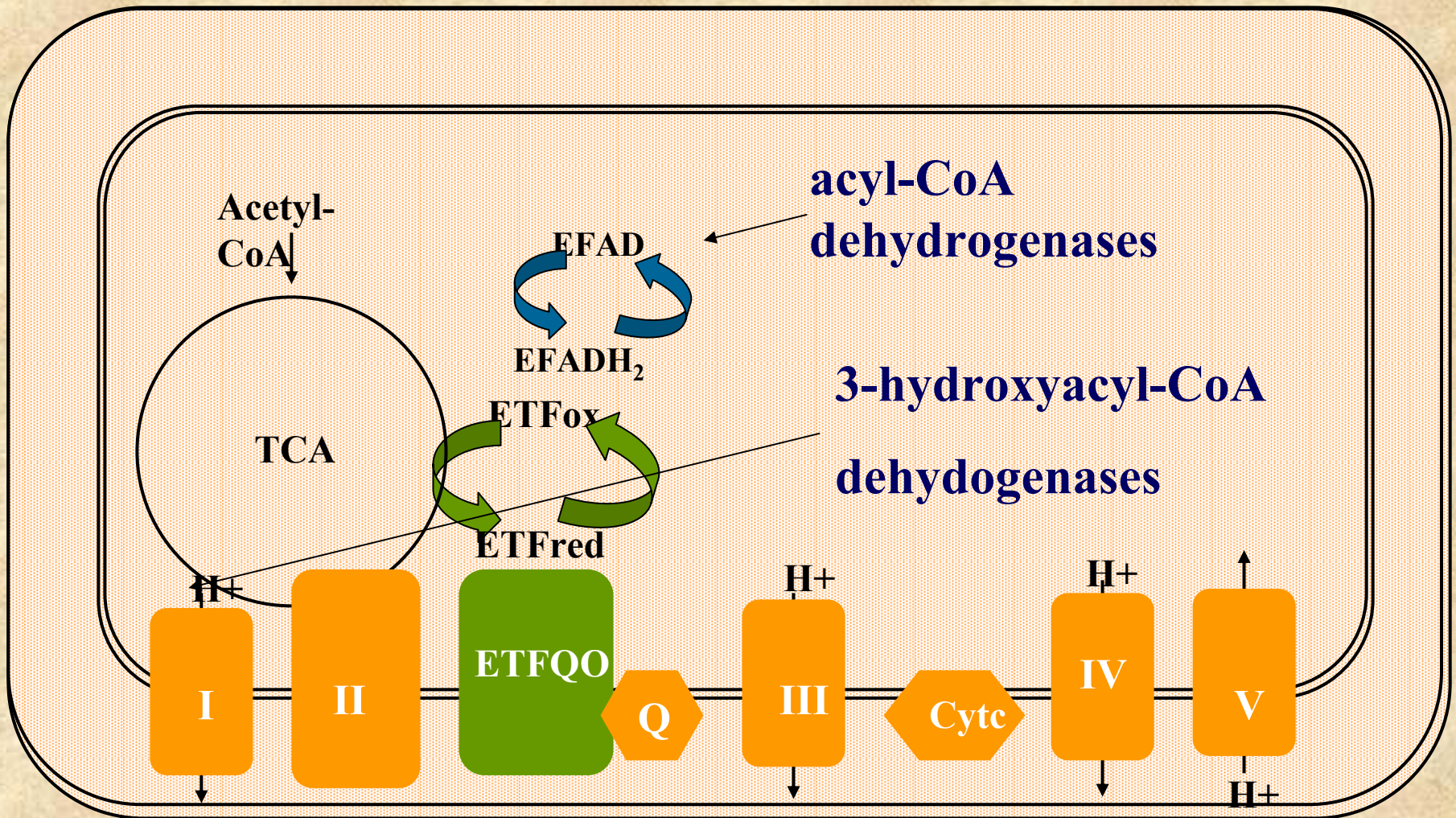
Clinical Chemistry

*Sheffield Children's
Hospital*





FAO & RES



Diagnosis of a respiratory chain defect

Clinical

Histological - staining, EM

Biochemical - complexes I, II/III, IV (?)V

muscle, liver, heart, fibroblasts

Polarography - only a very few centres

Mitochondrial mutations

NARP, MELAS, MERRF, tRNA's

Nuclear mutations

SCO2, SURF1, Cox10, Cox15

Diagnosis of a respiratory chain defect

In practise

often a balance of probabilities

Are fibroblasts worthwhile?

Many older children / adults

mtDNA mutations eg. MELAS

Neonates and infants

~ 95% due to nuclear defects

BUT

Isoforms in different tissues

Defect may not be “limiting” in fibroblasts

- **SCO2 - normal IV in fibroblasts**

Fatty acid oxidation assay

3 substrates

[9,10-³H]myristate, [9,10-³H]palmitate, [9,10-³H]oleate

Incubate monolayers in multiwell plates

24 wells - 3 substrates in duplicate (110 μmol/l)

2 hours at 37°C

Separate & count released ³H₂O

Assay protein / well

Activity ~ 5 nmol/mg/hr

expressed as % of 3-5 simultaneous controls

Definition of abnormal FAO

Mean of duplicate $\leq 70\%$ (2 full assays)

If all results not $\leq 70\%$

$\geq 5/9$ duplicate results $\leq 70\%$

Fibroblast FAO

Probable / definite respiratory chain defects

Clinical, biochemical, histological

50 patients over 10 years - all had a skin bx

Complexes measured in M or L - 32

Complexes (F) only - 14

Not measured - 4 (NARP, awaiting)

FAO and probable respiratory chain disease

FAO low in 37/50 cases (74%)

Complexes low in muscle/liver in 22/32 cases (69%)

Complexes low in fibroblasts 7/21 cases (33%)

- Complex I & V not measured
- overall function not assessed by complexes

34/50 most probable/definite RES

Clearly low complexes

Muscle and / or liver = 22

Fibroblasts (only) = 6

Mutation data or other = 6 (NARP/ tRNA & low PDH)

FAO & RES

FAO low in 19/34 highly probable/definite cases (56%)

FAO low in 7/7 cell lines with low complexes

- Low II/III - 2**
- Low III - 1**
- Low IV - 4**

FAO & RES

- **2 patients - isolated low I (M)**
 - both low fat oxidation (F)
- **3 patients had depletion**
 - 2 normal FAO
 - 1 abnormal FAO

Patient TR

Died ~ 10 months (suddenly)

Dilated cardiomyopathy

Excess fat deposition in heart and liver

Microscopically ↑ fibrous tissue

Patient TR

Fibroblast fatty acid oxidation

Myristate %

64 ± 19

Palmitate %

73 ± 20

Oleate %

70 ± 18 (n=5)

sl.↓ complex IV in fibroblasts (0.006) (0.007 - 0.036)

Mutant tRNA^{Ile}

- **Known tRNA isoleucine point mutations that can cause isolated cardiomyopathy**
- **A4317G**
- **A4269G**
- **A4300G**
- **C4320T**
- **A4295G**

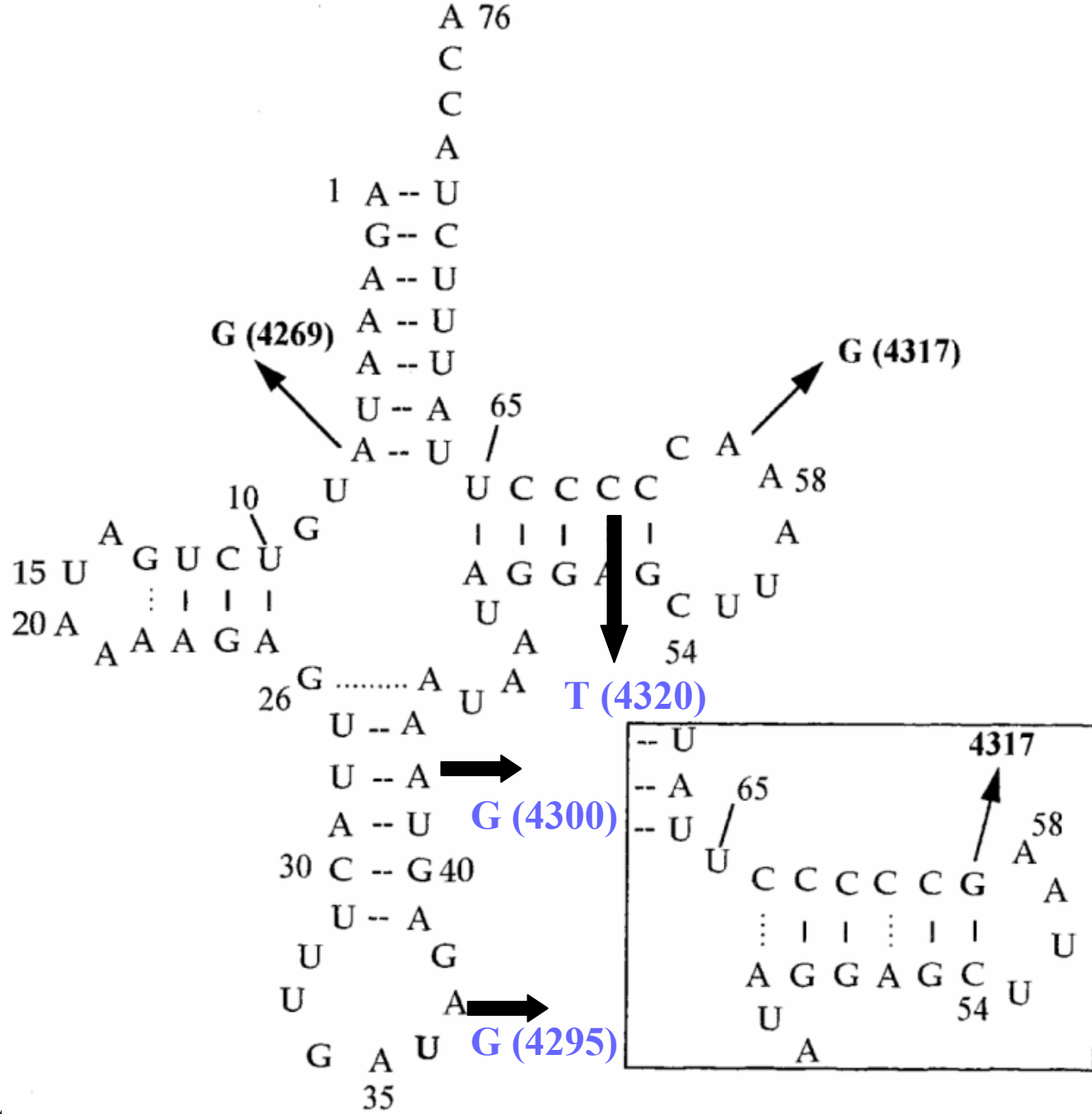
Mutant tRNA^{Ile}

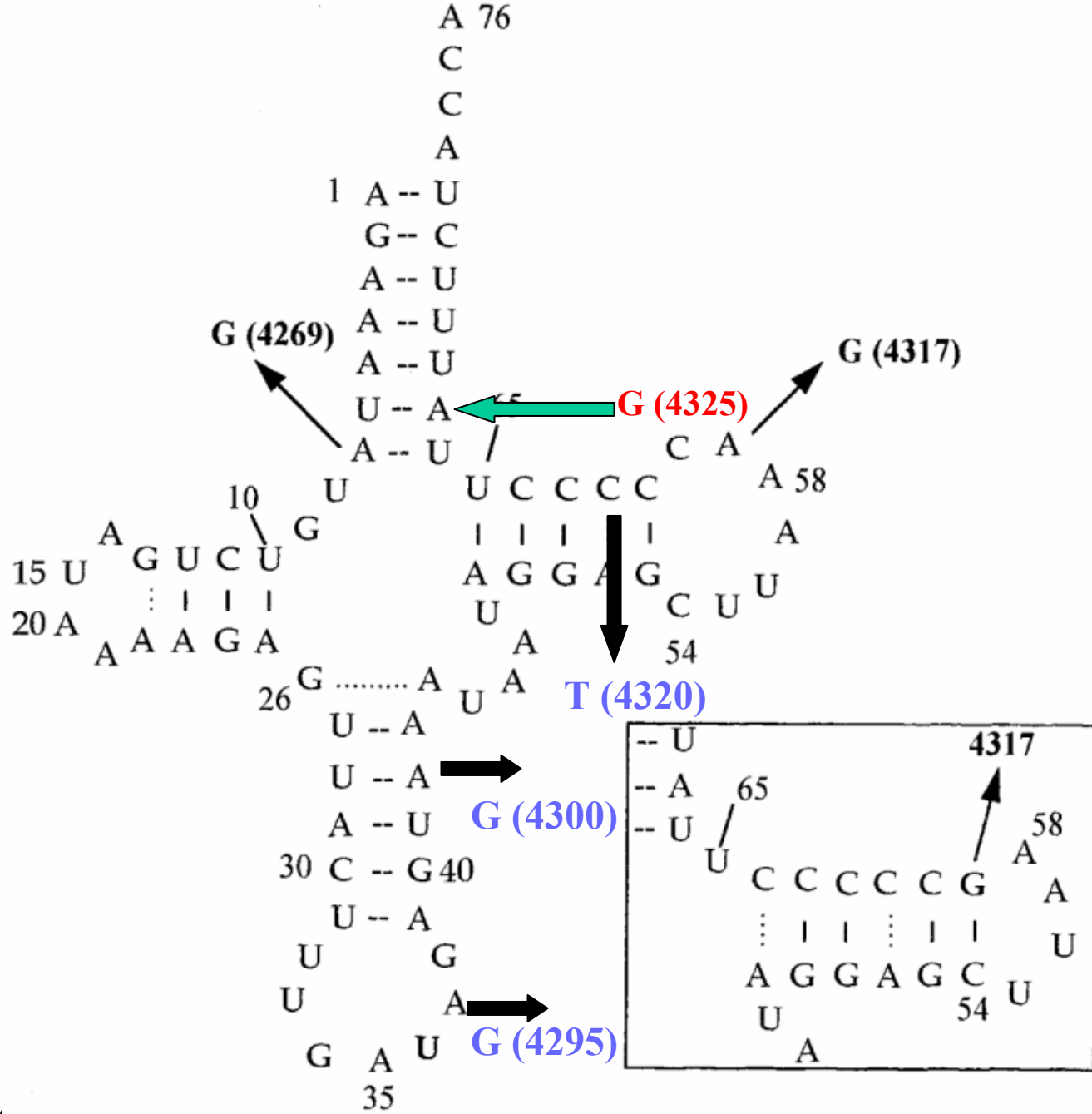
A4317G

↓ complex I & IV in heart

A4269G

↓ complex IV in skeletal muscle & brain





Mutant tRNA^{Ile}

A4317G (T loop)

- **reduces isoleucylation by 70%**
- reduction in mt protein synthesis

A4269G (acceptor stem)

- **isoleucylation not affected**
- **conformational changes leading to premature mt translation termination - isolated low complex IV**

A4325G - (?) effect possibly similar to A4269G

Patient OB

Gross motor delay at 14 months

CSF lactate 6 mmol/l

Fatty acid oxidation

Myristate %

51 ± 7.4

Oleate %

54 ± 9.0

(3 assays in duplicate)

Patient OB

Fibroblasts

complex II/III 0.173 (0.07-0.243)

complex IV **0.003** (0.007- 0.036)

Low IV (muscle)

SURF1 mutation

– **complex IV assembly**

Patient JT

Leigh's encephalopathy at 1 year

CSF lactate 3.9 mmol/l

Plasma lactate 2.9 mmol/l

Myristate %

57%

Palmitate%

70%

Oleate %

59%

(mean of 2 assays in duplicate)

Patient JT

Muscle complexes

complex I 0.215 (0.104-0.268)

complex II/III 0.093 (0.04-0.204)

complex IV 0.17 (0.14-0.034)

PDH - normal

***T8993G* present (NARP)**

Patient JT

- **Fibroblasts**
- ***T8993G* present at high level**
 - **ATPase-6 gene**
 - **Why low FAO?**

Patient NM

Female 24/40 gestation

pericardial effusion / cardiomegaly

Neonate

hypotonia, muscle weakness, poor feeder

hypertrophic cardiomyopathy

MRI

white matter, basal ganglia and cerebellar abnormalities

Plasma lactate

5-6 mmol/l

Patient NM

Muscle biopsy

- Myopathic findings
- Normal complexes, no mutations

Urine OA

- (?) suggestive of GAI
- DCA, 3(OH)isovalerate, isovalerylglycine 2(OH)glutarate

Patient NM

Myristate %

49 ± 4

Palmitate %

50 ± 6

Oleate %

50 ± 5

(3 assays in duplicate)

Fibroblasts complexes

II/III **0.048** (0.07 - 0.243)

IV **0.004** (0.007-0.036)

ATP production on digitonised fibroblasts

15% of controls

Fibroblast fat oxidation in detection of RES (?)

- Can detect a significant % of neonates / infants
- (?) 20 - 60%
- False positive rate - (?)
- Low fat oxidation seen in:-
 - Alstrom's
 - Laminopathy
 - Severe neonatal GSD IV
 - (?) overlaying !

Disadvantages

Defect not always expressed / present

Defect may be lost in culture

Difficulty of measuring Complex I ?!

Advantages of fibroblasts

- **Easy to obtain and grow**-repeat assays, storage, PM
 - **no excuse for muscle b_x without skin!!!!**
- **Less subject to secondary factors**
 - deterioration, nutrition, clinical state
- **Flux assays (intact cells)**
 - overall measure of energy metabolism
- **Complexes**
 - (?) I II, III, IV & ubiquinone
- **Digitonised fibroblasts**
 - **ATP production (great potential !!)**



15/06/2005

32



15/06/2005

33